

## ORIGINAL ARTICLE

Frank Smedts · Frans Ramaekers · Monique Link  
Ludmilla Lauerova · Sergey Troyanovsky  
Charles Schijf · G. Peter Vooijs

## Detection of keratin subtypes in routinely processed cervical tissue: implications for tumour classification and the study of cervix cancer aetiology

Received: 2 November 1993 / Accepted: 14 April 1994

**Abstract** We investigated the expression of keratin subtypes 7, 8, 10, 13, 14, 17, 18 and 19 in the normal cervix, in cervical intraepithelial neoplasia (CIN) lesions and in cervical carcinomas, using a selected panel of monoclonal keratin antibodies, reactive with routinely processed, formalin fixed paraffin embedded tissue fragments. The reaction patterns derived for each keratin antibody were compared with known expression patterns of the various epithelia, previously examined in frozen tissues. Although the reactivity of the antibodies was generally acceptable, considerable modifications to the manufacturers' staining instructions were often necessary. For some antibodies, which were previously thought to be reactive with fresh frozen tissue only, we developed staining protocols rendering them reactive with routinely processed material. As with previous findings in frozen sections we observed increasing expression of keratins 7, 8, 17, 18 and 19 with increasing grade of CIN. In cervical carcinomas the differences in keratin detectability between the main categories were more pronounced than in frozen sections, probably due to fixation and processing. For routine pathology, keratin phenotyping of cervical le-

sions may be of value in classification. The fact that keratin 7 was detected for the first time in reserve cells, and that this keratin was also found to be expressed in a considerable number of CIN lesions and cervical carcinomas supports the suggestion that reserve cells are a common progenitor cell for these lesions.

**Key words** Intermediate filament proteins · Cervix Neoplasia · Immunohistochemistry

### Introduction

Keratins comprise a family of at least 20 intermediate filament proteins catalogued from 1 to 20 exhibiting a tissue specific distribution pattern in epithelia [15, 17]. Their distribution has been shown to be partly conserved during neoplastic transformation [23]. During this process additional keratins may become expressed, or others may be lost, depending on the degree of differentiation of the tumour under investigation. In many cases the tumour keratin phenotype indicates the tissue type from which it originated, allowing a more exact classification [23].

In previous studies [5, 6, 12, 16, 25, 26, 27, 28, 30] we extensively investigated the keratin expression patterns in the normal cervix, in metaplastic epithelia, in cervical intraepithelial neoplasia (CIN) and in cervical cancer, using recently developed monoclonal and polyclonal antibodies, reacting separately with most of the known keratin subtypes [10]. The most salient features of these assays, all carried out on frozen tissue sections, may be summarized as follows: *ectocervical nonkeratinizing squamous epithelium* shows a keratin pattern characterized by intense expression of keratins 4 and 13. In addition, keratins specific for basal cell compartments, (5, 14, and 19) are also found. The expression pattern in *endocervical columnar cells* is characteristic of the keratins found in most of the so called simple epithelia (keratins 7, 8, 18 and 19). Surprisingly some expression of keratins 4, 15 and 16, normally related to squamous dif-

F. Smedts (✉)  
Department of Pathology, Canisius Wilhelmina Hospital,  
Weg door Jonkerbos 100,  
NL-6432 SZ, Nijmegen, The Netherlands

F. Ramaekers  
Department of Molecular Cell Biology and Genetics,  
University of Limburg, Maastricht, The Netherlands

M. Link · G. P. Vooijs  
Department of Pathology, University of Nijmegen,  
The Netherlands

L. Lauerova  
Department of Cellular and Molecular Oncology,  
Masaryk Memorial Cancer Institute, Brno, Czechoslovakia

S. Troyanovsky  
Cancer Research Centre,  
The Russian Academy of Medical Sciences, Moscow, Russia

C. Schijf  
Department of Obstetrics and Gynaecology,  
University of Nijmegen, Nijmegen, The Netherlands

ferentiation, are also noted in columnar endocervical cells.

*Endocervical reserve cells* combine expression of keratins typical of squamous epithelium as well as keratins characteristic of simple epithelium. In addition keratin 17 was found to be specific for reserve cells in the cervix. The keratins present in metaplastic squamous epithelium, reflect the degree of squamous maturation [26]. When this epithelium exhibits high expression levels of keratins typical of simple epithelia and fewer keratins characteristic of nonkeratinizing epithelia it is in general morphologically immature. Metaplastic epithelia showing the opposite keratin expression pattern are usually more mature. In the keratin phenotype of CIN, *CIN I* and *CIN II* cannot be distinguished on the basis of their keratin expression patterns. Most of these lesions show patterns reminiscent of that found in ectocervical epithelium, while 10% express the keratins typical of the progenitor reserve cells in addition. In *CIN III* the number of cases containing these reserve cell keratins has increased up to 50%. Previously we postulated that the group of CIN lesions with express reserve cell keratins may well be premalignant in nature [25, 26]. This theory is to a certain extent supported by the keratin expression patterns observed in cervical cancer [27]. In *keratinizing squamous cell carcinoma of the cervix* a complex keratin expression pattern is found, including all keratins found in reserve cells, as well as keratins indicating squamous maturation and keratinization. The keratin make up of *large cell nonkeratinizing carcinoma* was somewhat less complex, but again the basic reserve cell keratin expression pattern is usually observed. *Adenocarcinomas* also express a number of typical reserve cell keratins. We have interpreted these findings as support for the hypoth-

esis that both squamous cell carcinomas and adenocarcinomas of the cervix have a common progenitor cell; the reserve cell. The results of the studies outlined were all based on observations in frozen tissue material. Recently monoclonal keratin antibodies reactive with routinely processed tissues have made it possible to investigate whether these results are reproducible in paraffin embedded tissue. In the course of the study we found that protocols for the application of these antibodies often had to be considerably modified to obtain optimal results. Furthermore the observations have allowed some modifications to our views on cervical keratin expression. Finally, possibilities regarding the applications of these antibodies in general practice are evaluated.

## Materials and methods

Routinely processed formalin fixed and paraffin embedded (tumour) tissue blocks were used. The tissue fragments analysed represented diathermy loop excision specimens and cervical cone biopsies from 52 women with cytologically verified dysplasia. The tissue samples representing 41 cases of cervical carcinoma were taken from hysterectomy specimens and excision biopsies, and included 3 cases with both material from the primary cervical carcinoma and a lymph node metastasis. Many cases comprised more than one tissue fragment per block, which were all analysed as one case. A total of approximately 250 tissue fragments were analysed, representing both normal endo- and ectocervical epithelia, metaplastic epithelia, the three grades of CIN and cervical carcinoma. Often more than one type of epithelium could be distinguished in the same fragment. As a result non-keratinizing ectocervical epithelium was detected in 50 specimens, endocervical columnar epithelium in 58 specimens, reserve cells in 29 specimens, immature squamous metaplastic epithelium in 16 specimens and mature squamous metaplastic epithelium in 19 specimens. CIN I was diagnosed in 16 specimens, CIN II in 25 specimens and CIN III in 26 specimens. There were 4 keratinizing squamous cell

anti rabbit IgG; *RaMPo* horse radish peroxidase conjugated rabbit anti mouse IgG

**Table 1** Overview of the characteristics of the antibodies used in this study and the most important steps of the staining protocols. RT roomtemp; *SwaRPo* horse radish peroxidase conjugated swine

Antibody	Ig subtype	Species	Keratin(s) recognized	Pronase	Antibody Dilution	Incubation time	Detection system	Reference	Source
p Ker	Polyclonal	Rabbit	several	+	1:80	1 h/RT	SwaRPo	33	Euro-Diagnostics, Apeldoorn, The Netherlands
34 $\beta$ 12		Mouse	1,5+?	+	1:500	12 h/4° C	RaMPo/SwaRPo	4, 7	ENZO, Biochem, NY, USA
OV-TL 12/30	IgG1	Mouse	7	–	1:2	12 h/4° C	RaMPo	18, 22	BioGenex Labs, München, Germany
CAM 5.2	IgG2a	Mouse	8	+	1:20	1 h/RT	RaMPo	13	Becton and Dickinson, Etten Leur, The Netherlands
DE-K-10 AE8	IgG1	Mouse	10	–	1:20	12 h/4° C	RaMPo/SwaRPo	9	BioGenex Labs
		Mouse	13	–	1:2	1 h/RT	RaMPo	7, 8	Sanbio, Uden, The Netherlands
LLOO2*	IgG2a	Mouse	14	–	undiluted	12 h/4° C	RaMPo/SwaRPo	10	BioGenex Labs
E3	IgG2b	Mouse	17	+	1:2	1 h/RT	RaMPo	29	Dr S. Troyanovski, Moscow, Russia
DC10	IgG1	Mouse	18	+	1:10	1 h/RT	RaMPo/SwaRPo	11	BioGenex Labs
DA7	IgG1	Mouse	18	+	1:10	1 h/RT	RaMPo/SwaRPo	11	BioGenex Labs
RCK108	IgG1	Mouse	19	+	undiluted	1 h/RT	RaMPo	unpublished	BioGenex Labs

\* Prior to staining the slides were placed in demineralized water and cooked for 10 min in a microwave oven

carcinomas, 19 large cell nonkeratinizing squamous cell carcinomas, 11 adenocarcinomas (of which 2 were of the clear cell variety), 3 neuroendocrine carcinomas and 2 adenosquamous carcinomas. In 3 cases we also examined the keratin phenotype of lymph node adenocarcinoma metastases, of which one was of the clear cell variety. The subepithelial, stromal tissues were meticulously examined for keratin expression in all cases. The diagnoses in each individual case had been verified by at least three pathologists. Where there was a discrepancy, the case was discarded from the study.

Ten monoclonal antibodies and one polyclonal antibody were used in this study. Their characteristics and references [4, 7, 8, 9, 13, 14, 18, 20, 21, 22, 29] are summarized in Table 1. The horseradish peroxidase conjugated swine anti rabbit IgG and the horseradish peroxidase conjugated rabbit anti mouse IgG were obtained from Dakopatts, Denmark.

Considerable modifications to the staining procedures as indicated in the manufacturers' instructions were often necessary to obtain immunoreactivity with certain antibodies. The modifications to the routinely used staining procedure giving the best results, are indicated in Table 1. All tissue fragments had been fixed in 4% buffered formalin for at least 24 h but not longer than 72 h, before being processed through paraffin for routine diagnosis. The blocks were then stored in our archive for at least 1 year, prior to retrieval for this project. From these blocks 4 µm thick sections were cut, and deparaffinized with xylene and ethanol. Pronase (0.1% Sigma, St Louis, USA) digestion in phosphate buffered saline (PBS), at 37° C, for 10 min was necessary to obtain optimal results for certain antibodies (see Table 1). For LLOO2 the slides were not treated with pronase but placed in demineralized water and cooked for 10 min in a microwave oven at 750 W. Endogenous peroxidase activity was blocked by immersion for 20 min in 3% hydrogen peroxide in PBS, after which the slides were rinsed in PBS. After preincubation with 20% normal swine serum for 15 min the primary antibody was applied at the appropriate dilution for the time period indicated (see Table 1). After washing in PBS, the appropriately diluted peroxidase conjugated secondary antibody was applied in PBS. In some cases an amplification step was applied, followed by a third series of washing steps. Peroxidase activity was detected with 3-amino-9-ethylcarbazole (AEC; Aldrich Chemical Company, St Louis, Mo., USA) by incubation for 10 min, the slides counterstained with Harris' haematoxylin and mounted with Kaisers' glycerine.

## Results

The results are summarized in Fig. 1 and depicted in Figs. 2–5. In general, the antibodies used showed satisfactory to excellent staining results when the modifications in the immuno-detection protocols (as summarized in Table 1) were followed. 34β12, OV-TL 12/30, DE-K-10, LLOO2, E3 and DA7 generally displayed strong immunoreactivity, while AE8 showed a moderately strong expression. The immunoreactivity of E3 was generally even more intense than the patterns previously observed in the frozen sections. DC10 reactivity was constantly less than DA7 although both react with keratin 18. CAM 5.2 and RCK 108 in contrast stained fewer cells, less intensely in paraffin sections [25, 26], than previously observed in frozen tissue sections. Attempts to augment activity of the various antibodies by cooking in a microwave oven were only successful for LLOO2, while an enzyme predigestion often enhanced immunoreactivity considerably (Table 1). We will describe the reactivity patterns of the individual antibodies for the different types of epithelial cells in normal cervix extensively in


order to illustrate their usefulness for keratin immunophenotyping in routinely processed tissue material.

In ectocervical nonkeratinizing epithelium (Figs. 1a, 2a–g) the polyclonal keratin antibody and 34β12 were found to stain the ectocervical epithelium in all cases, usually with an intense reaction throughout the full thickness of the epithelium. The antibodies OV-TL 12/30 (Fig. 2a), CAM 5.2 (Fig. 2b) and E3 (Fig. 2f) detecting keratins 7, 8 and 17, respectively, did not react in ectocervical epithelium. In 13 cases keratin 18 was detected only by the antibody DA7 (Fig. 2g) which revealed a weak staining reaction in most cells of the basal cell compartment and sporadically in the parabasal and intermediate cell compartment. DC10, also reactive with keratin 18, remained negative in all cases. RCK 108, recognizing keratin 19, was found to stain the basal cells of half of the specimens. The keratin 10 antibody DE-K-10 (Fig. 2c) occurred in dispersed cells above the intermediate and superficial cell compartments in 14 cases. Keratin 13 detected with the antibody AE8 (Fig. 2d) decorated most cells above the basal layer, usually staining intensely. Keratin 14 (Fig. 2e), as detected by the antibody LLOO2, was always present in the basal and parabasal cell layer. In the more superficial layers the number of cases staining and the staining intensity decreased.

In endocervical columnar cells and reserve cells (Figs. 1b, 2 h–n) from the tissue fragments of 58 patients in which we observed columnar cells, the polyclonal antibody revealed an intense staining reaction. 34β12 only stained some cells in 10 cases with moderate intensity. These cells stained with the simple keratin antibodies OV-TL 12/30 (keratin 7, Fig. 2h), CAM 5.2 (keratin 8, Fig. 2i), DA7 (keratin 18, Fig. 2n) and RCK 108 (keratin 19), with moderate to strong intensity. The keratin 18 antibody DA7 showed a more distinct expression than DC10. Immunostaining for DE-K-10, (keratin 10, Fig. 2j), AE8 (keratin 13, Fig. 2k) and E3 (keratin 17, Fig. 2m) was not found. LLOO2 (keratin 14) was only found sporadically in a few cases. However, this keratin was usually not detected (Fig. 2l). Reserve cells were intensely stained by the polyclonal keratin antibody and also 34β12 in all 28 cases. Of the simple keratin antibodies, OV-TL 12/30 (keratin 7, Fig. 2h) showed an intense staining in the reserve cells in all cases. Also keratin 8 as detected by CAM 5.2 (Fig. 2i) was moderately expressed. Again, staining with the keratin 18 antibody DA7 (Fig. 2n) was more intense than DC10. Keratin 19 as detected by the antibody RCK 108 showed a moderate reactivity with most reserve cells. Keratin 17 (Fig. 2m), related to squamous and basal cell differentiation was present in 25 cases, but the staining intensity with E3 varied considerably from case to case. DE-K-10 (keratin 10, Fig. 2j) and AE8 (keratin 13, Fig. 2k) immunoreactivity related to squamous differentiation, were not found in reserve cells. LLOO2 (keratin 14, Fig. 2s) however, was weakly detectable in a few cases.

The results for squamous metaplastic epithelia, CIN lesions and cervix carcinomas as obtained with the various antibodies will be summarized briefly with emphasis

**Fig. 1** Pattern of keratin expression in (a) normal ectocervical epithelium, (b) columnar and reserve cells, (c) immature squamous metaplasia, (d) mature squamous metaplastic epithelium, (e) cervical intraepithelial neoplasia (CIN) I, (f) CIN II, (g) CIN III, (h) keratinizing squamous cell carcinoma, (i) nonkeratinizing squamous cell carcinoma, (j) adenocarcinoma, (k) adenosquamous carcinoma and (l) neuroendocrine carcinoma. The keratins are indicated by their respective number according to Moll's catalogue [1].  $\square$  negative;  $\blacksquare$  1–25%;  $\square$  25–50%;  $\square$  50–75%;  $\blacksquare$  75–100% of cases positive. Staining intensity is indicated by the shading of the box; *black* – intense, *horizontal lines* – moderate to strong, *parallel oblique lines* – mild to moderate or intense, *dots* – staining of single cells. *K* keratin(s); *S* superficial cells; *I* intermediate cells; *B* basal cells; *PB* parabasal cells; *C* columnar cells; *RC* reserve cells



on the most salient features. For details we refer to Figures 1c–l and Figures 3–5.

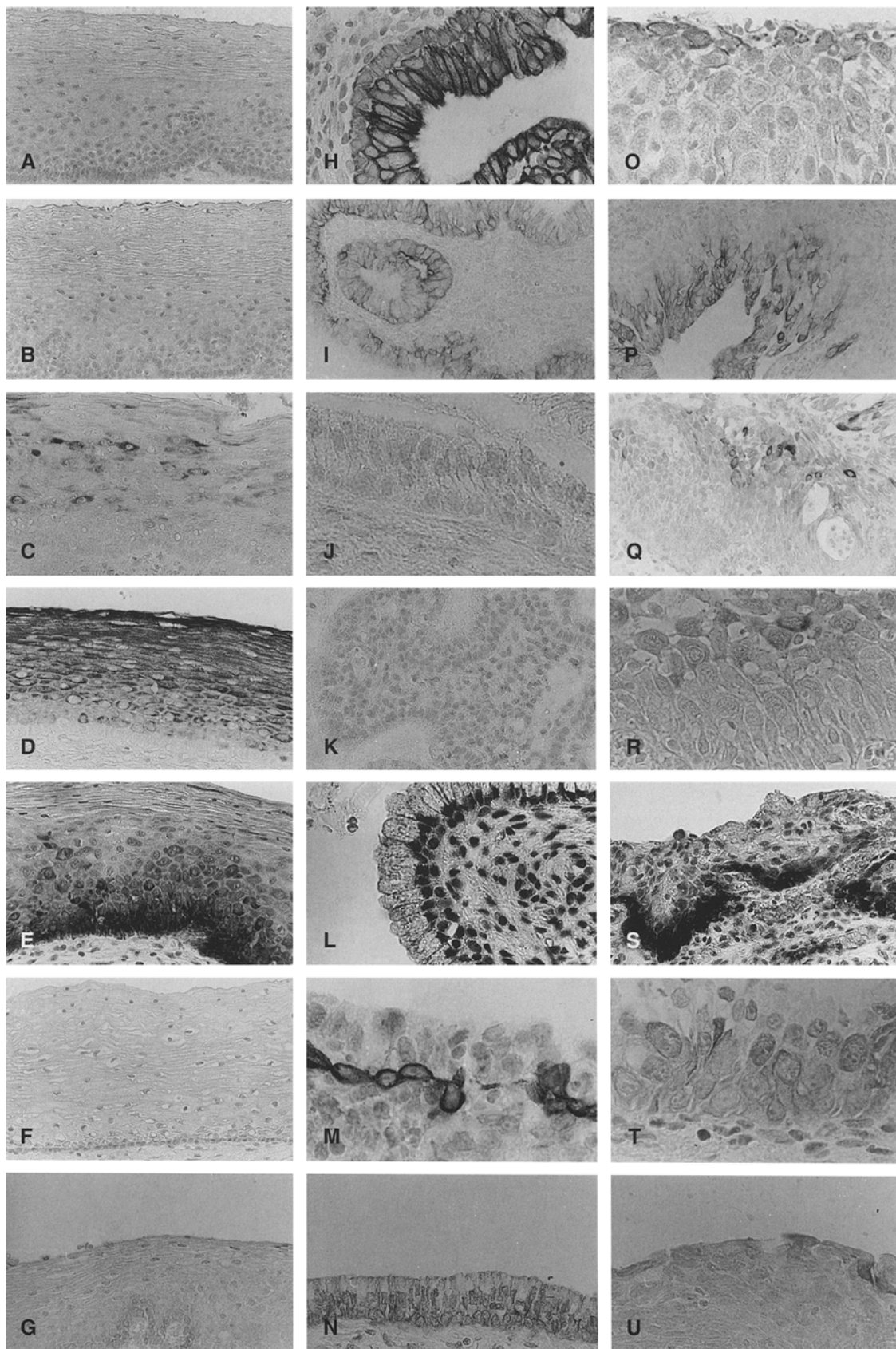
In immature and mature metaplastic squamous epithelium (Fig. 1c, 2o–u) keratin expression generally reflected the level of maturation. In immature squamous metaplasia (Fig. 2o–u) the keratin antibodies OV-TL 12/30 (Fig. 2o) and DA7 (Fig. 2u), detecting the simple keratins 7 and 18, were moderately positive, while keratin 8 (CAM 5.2, Fig. 2p) was less constantly detected. Keratin 17 as detected by E3 (Fig. 2t) was usually present. Keratins 10 and 13 detected with DE-K-10 (Fig. 2q) and AE8 respectively (Fig. 2r) and indicating squamous maturation, were found in approximately half of the cases of immature squamous metaplasia, with varying expression levels, while keratin 14 (LLOO2, Fig. 2s) was consistently present.

In mature squamous metaplastic epithelium (Fig. 1d) expression of the simple keratin markers had decreased considerably compared to immature squamous metaplasia.

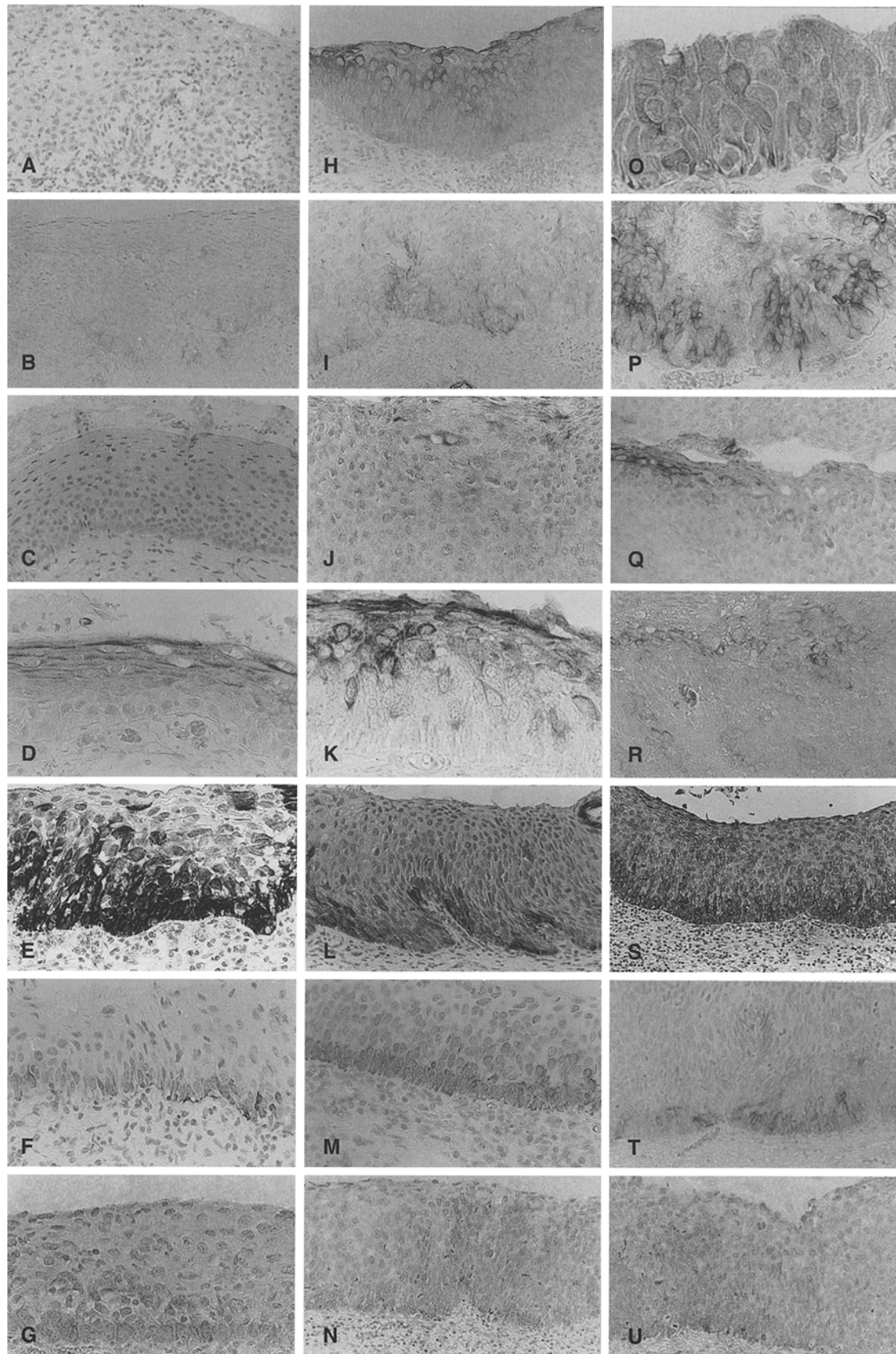
There was only slight reactivity for OV-TL 12/30 (keratin 7), CAM 5.2 (keratin 8) and DA7 (keratin 18). In a few cases positive reactivity was also observed for E3 detecting keratin 17. However, the intensity and the number of cases reactive for keratin 10 (DE-K-10), keratin 13 (AE8) and keratin 14 (LLOO2) compared to their expression in immature squamous metaplasia had increased slightly, while keratin 10 (DE-K-10), was less constantly found.

CIN (Figs. 1e–g, 3a–u) showed keratin expression in different grades which was often irregular. The intercel-

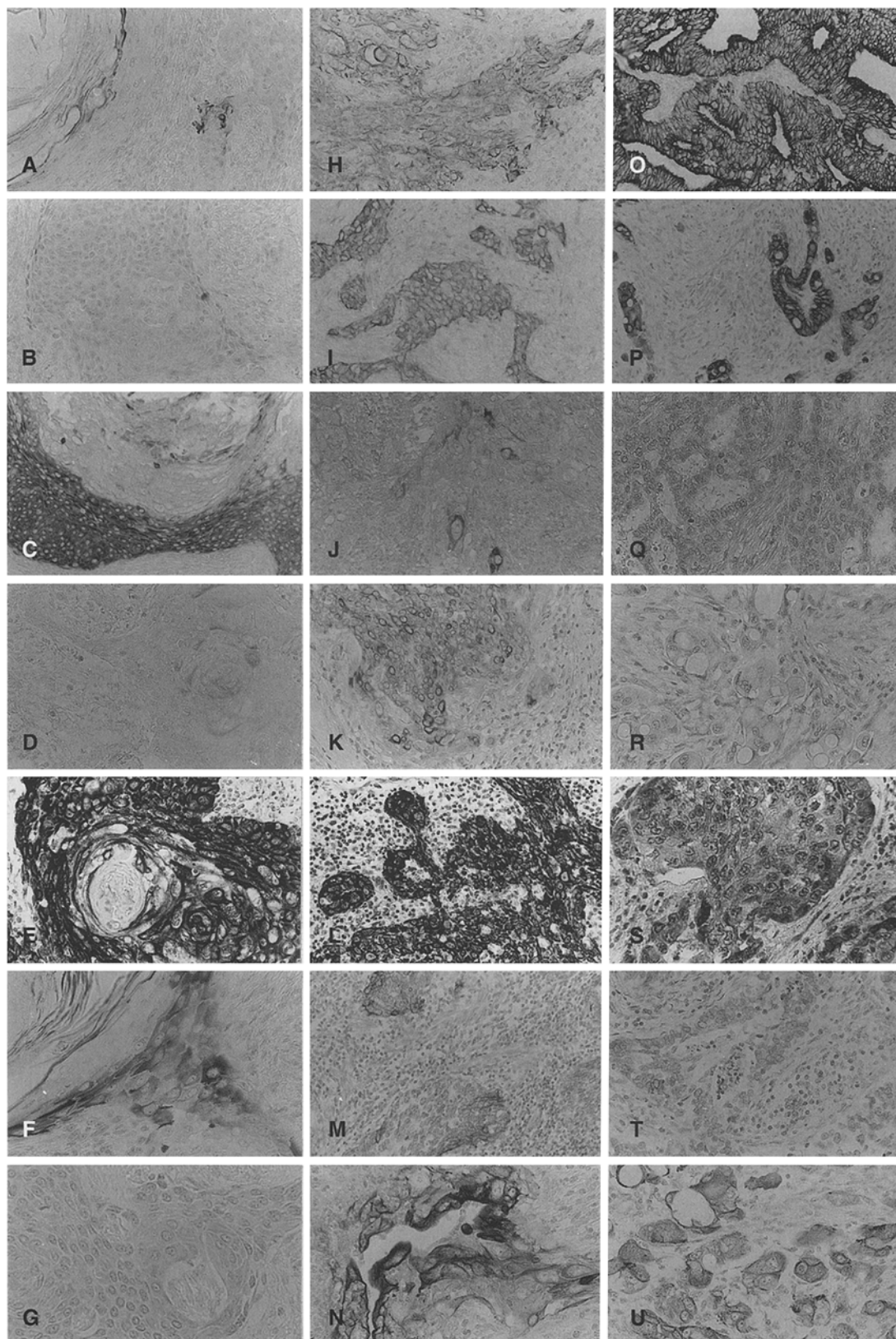
**Fig. 2** Immunoperoxidase staining patterns of formalin fixed paraffin embedded sections from (a–g) normal ectocervical epithelia, (h–n) columnar and reserve cells and (o–u) immature squamous metaplasia, after staining with (a, h, o) OV-TL 12/30 (keratin 7), (b, i, p) CAM 5.2 (keratin 8), (c, j, q) DE-K-10 (keratin 10), (d, k, r) AE8 (keratin 13), (e, l, s) LLOO2 (keratin 14), (f, m, t) E3 (keratin 17) and (g, n, u) DA7 (keratin 18)





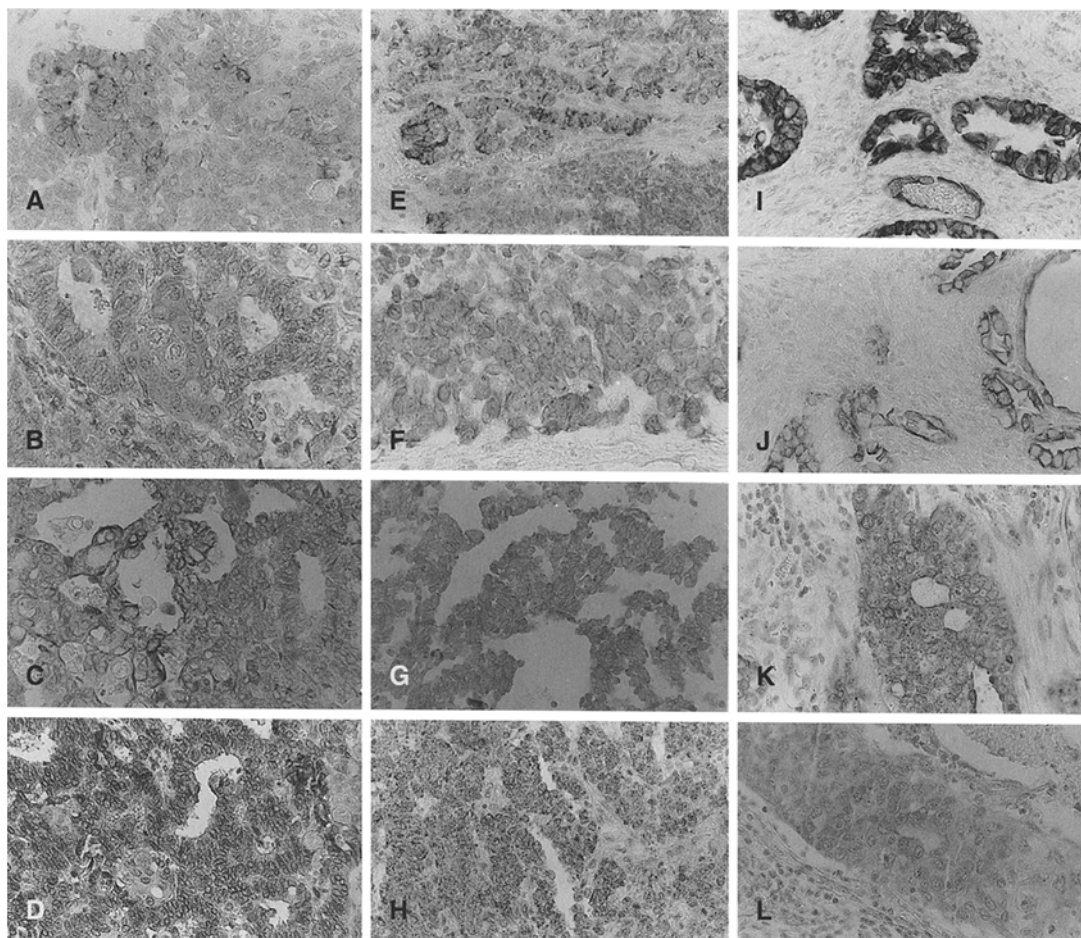


**Fig. 3** Immunoperoxidase staining patterns of formalin fixed paraffin embedded sections from (a–g) CIN I lesions, (h–n) CIN II lesions and (o–u) CIN III, after staining with (a, h, o) OV-TL 12/30 (keratin 7), (b, i, p) CAM 5.2 (keratin 8), (c, j, q) DE-K-10 (keratin 10), (d, k, r) AE8 (keratin 13), (e, l, s) LLOO2 (keratin 14), (f, m, t) E3 (keratin 17) and (g, n, u) DA7 (keratin 18)



**Fig. 4** Immunoperoxidase staining patterns of formalin fixed paraffin embedded sections from (a–g) keratinizing squamous cell carcinomas, (h–n) non-keratinizing squamous cell carcinomas (o–u) and adenocarcinoma after staining with (a, h, o) OV-TL

12/30 (keratin 7), (b, i, p) CAM 5.2 (keratin 8), (c, j, q) DE-K-10 (keratin 10), (d, k, r) AE8 (keratin 13) (e, l, s) LLOO2 (keratin 14), (f, m, t) E3 (keratin 17) and (g, n, u) DA7 (keratin 18)



**Fig. 5** Immunoperoxidase staining patterns of formalin fixed paraffin embedded sections from (a–d) adenosquamous carcinomas of the cervix, (e–h) neuroendocrine carcinomas of the cervix and (i–l) lymphnode metastasis of cervical adenocarcinomas after staining with (a, e, i, j) OV-TL 12/30 (keratin 7), (b, f, k, l) DA7 (keratin 18), (c, g) RCK 108 (keratin 19), and (d, h) LLOO2 (keratin 14)

lular variation in staining intensities was high. As might be expected those keratins related to stratified epithelium (keratins 13, 14 and sometimes 10) were the most prominent constituent of the cytoskeleton of this type of epithelium. The number of lesions expressing keratin 10 (Fig. 3c, j, q) and keratin 13 (Fig. 3d, k, r) decreased slightly with increasing severity of CIN, this was also the case for the keratin 14 antibody, LLOO2 (Fig. 3e, l, s).

In only a small portion of the CIN I lesions simple keratin antibodies OV-TL 12/30 (keratin 7, Fig. 3a), CAM 5.2 (keratin 8, Fig. 3b) and DA7 (keratin 18, Fig. 3g) were found to react. In the CIN II lesions these keratins were expressed in a higher percentage of samples and in CIN III lesions expression of these simple keratins had increased up to more than 50% of cases (Fig. 3o, p, u). The intensity of labelling had usually increased. The percentage of lesions expressing keratin 17 increased with the severity of dysplasia (Fig. 3f, m, t). Keratin 19 was always found, usually in the basal cell layer.

It was also observed in the other epithelial layers with increasing severity of CIN.

In carcinomas (Figs. 1h–l, 4, 5) keratin expression was related to type and grade of differentiation. The expected keratins of the stratified epithelial type keratin 10 recognized by DE-K-10, keratin 13 recognized by AE8 and keratin 14 recognized by LLOO2 were always observed in *keratinizing squamous cell carcinoma* (Figs. 1h, 4c, d). The simple keratins were only sporadically found in a single case, as detected by OV-TL 12/30 (keratin 7, Fig. 4a), CAM 5.2 (keratin 8, Fig. 4b) and DA7 (keratin 18, Fig. 4g). In the *nonkeratinizing carcinomas* (Fig. 1i) the stratified epithelial type keratins were found in approximately half of the cases (Fig. 4j, k). The simple keratins were frequently found, although there were major differences between cases with regards the number of positive cells (Fig. 4h, i, m). As could be expected, these simple keratins were strongly expressed in the *adenocarcinomas* (Figs. 1j, 4o, p, u). The squamous type keratins were not found (Fig. 4e, l, s). Keratin 17 as detected by E3 was found in only 2 keratinizing squamous cell carcinomas (Fig. 4f), in the majority of nonkeratinizing squamous cell carcinomas (Fig. 4m) and only sporadically in adenocarcinomas (Fig. 4t). RCK 108, detecting keratin 19, showed a similar staining pattern as compared to E3 in the squamous cell carcinomas. As expected, however all adenocarcinomas expressed keratin 19.



The stratification related keratins 10 and 13 were not detected (Fig. 4q, r). Keratin 14 however was found (Fig. 4e, l, s) in all three types.

In the 2 cases of *adenosquamous carcinoma* (Fig. 1k, 5a–e) expression of the stratification related keratins 10 and 13 was not noted. Keratin 14 (Fig. 5d) was sometimes present. All the simple keratins, keratins 7 (Fig. 5a), 8, 18 and 19 (Fig. 5c), were usually found in the adenocarcinomatous component. Strikingly in one case keratin 18 (Fig. 5b) was expressed weakly in the squamous component and not in the adenocarcinomatous component. Keratin 17 was not detected. In the 3 cases in which the relatively infrequent *neuroendocrine carcinoma* (Figs. 1l, 5e–h) was diagnosed only keratins 8, 18 (Fig. 5f) and 19 (Fig. 5g) and oddly keratin 14 (Fig. 5h), were observed, usually in the majority of cells. Keratin 7 (Fig. 5e) was sporadically present in one case.

In 3 cases of adenocarcinoma we were able to compare the keratin expression pattern of the primary tumour and the autologous lymph node metastasis. The reaction patterns were very similar (Fig. 5i, l) with the intensity of expression approximately the same in primary and metastatic tumour.

## Discussion

In general most of the antibodies used in this study displayed a staining pattern similar to that previously described in studies in frozen material. However in the formalin fixed paraffin embedded tissue from keratinizing and nonkeratinizing squamous cell carcinomas, keratins 8, 10, 13, 17, 18, 19 were less constantly expressed than in frozen tissue studies. In cervical adenocarcinomas there was a better correlation.

We noted a number of quantitative and qualitative differences to data found in the literature. The staining intensities of some of the antibodies was lower than found in frozen tissues, as for example in keratin 18 antibodies DA7 and DC 10, the keratin 7 antibody OV-TL 12/30, and the keratin 10 and keratin 13 antibodies DE-K-10 and AE8.

As observed by Gigi-Leitner et al. [6], Moll et al. [16] and ourselves, reserve cells stained for keratin 18 even in paraffin sections. Gigi-Leitner et al. [6] found essentially no labelling in immature squamous metaplasia with the keratin 18 antibody they used, which we did in both this and a previous study [25]. In contrast with the results of Levi et al. [12] and in keeping with our own previous results keratin 13 [25] was not found in reserve cells. We also confirm the gel-electrophoretic studies of Moll et al. [16] with regards the presence of the various keratins in the cervix, but in addition show which individual cell types contain the respective keratins. It became obvious that often considerable modifications to the standard procedure were necessary in order to obtain optimal results in routinely processed tissue material. Enzymatic pretreatment of slides usually gave results superior to the non-enzymatic method of microwaving the slides.

Keratin expression in frozen material from the normal cervix, premalignant lesions and cervical carcinomas have been described extensively [16, 25]. A comparison between previous studies and our own, using archival formalin fixed paraffin embedded tissue, shows a number of new characteristics of keratin expression in the cervix.

The most striking observation is the expression of keratin 7 in reserve cells. In the cervix this keratin subtype has so far only been demonstrated in columnar cells and in a few CIN III lesions [18] but not in reserve cells with the antibody RCK 105. We found this keratin polypeptide to be a constituent of the cytoskeleton of most reserve cells when using antibody OV-TL 12/30, and showed that it remained present during immature squamous metaplasia. It was also found sporadically in mature squamous metaplastic epithelium, but was not present in ectocervical epithelium. With increasing severity of CIN an increase in keratin 7 expression was noted. Keratin 7 was present in most carcinomas except for the keratinizing variety, expressing keratin 7 only in a few dispersed cells.

In squamous cell carcinomas keratin 7 expression is apparently related to the direction or degree of differentiation. This was also observed in studies in frozen tissues [27]. The fact that keratin 7 has been observed in epithelia in which it was previously considered absent may be explained on the basis of the high affinity of OV-TL 12/30 for its keratin epitope and the high titre of the antibody. In contrast to what has been found with antibody RCK 105, OV-TL 12/30 displayed a strong reactivity with endocervical reserve cells in frozen tissue specimens. In gel-electrophoretic studies OV-TL 12/30 reacts with keratin 7 [22] and in studies on frozen materials its reactivity is as strong as, or stronger than observed with other antibodies to keratin 7 (for example RCK 105). It does not show any unexpected immunoreactivity, which would make us suspect spurious crossreactivity with another cellular component. The immunoreactivity pattern of the OV-TL 12/30 in formalin fixed paraffin embedded tissue specimens [18] is comparable to that of other keratin 7 antibodies, when applied to frozen sections [22], indicating that formalin fixation does not change keratin 7 epitopes in an uncontrollable manner.

Expression of keratin 17 was more intense in CIN lesions after formalin fixation and paraffin embedding than observed previously in frozen sections. Keratin 17 was however not found in all carcinomas, in contrast to what was observed in frozen tissue sections. One suggestion to explain this discrepancy could be an effect of pronase treatment on the exposure of the E3 epitope.

Using the DA7 antibody we sometimes observed minor expression of keratin 18 in ectocervical epithelium.

Surprisingly keratin 14 and 19 were found in cervical neuroendocrine carcinomas. Keratin 19 has previously been observed in some small cell lung carcinomas [2], while keratin 14 has not yet been detected in such neoplasms. Keratin expression in clear cell carcinomas of the cervix comprises keratins 7, 8, 14, 18 and 19. Keratin

17 usually observed in endocervical adenocarcinomas, was not detected.

Although this study was performed with a smaller panel of keratin antibodies when compared with previous investigations, it still allows interpretation along the lines previously described. Central to any interpretation is the role of the reserve cells. When these cells proliferate into a CIN lesion, the reserve cell keratin phenotype is maintained in a number of cases. We postulated earlier [25, 26, 27] that this subclass of CIN lesions is progressive in nature, while those that acquire a keratin expression phenotype of ectocervical epithelium, losing simple keratin expression, are regressive in nature. In frozen tissue studies we observed expression of keratins 8, 17 and 18 in practically all cervical carcinomas, which complies with the general rule that keratin expression is in part maintained upon malignant transformation. This was not found in all formalin fixed, paraffin embedded carcinoma samples and justifies further investigation into antigen retrieval protocols, and the sensitivity enhancement of detection systems.

The keratin expression patterns of the carcinomas are not always consistent with their classification on morphological grounds. For example keratin 10, considered as an absolute marker for keratinization, is expressed in a number of carcinomas which on the basis of morphological criteria have been classified as being of the nonkeratinizing variety. Furthermore, a number of morphologically classified squamous cell carcinomas showed a keratin phenotype reminiscent of adenocarcinomas. We feel that future research should look into these keratin phenotypes in relation to prognosis. It is quite possible that some cervical carcinomas classified as nonkeratinizing carcinomas would, on the basis of keratin expression patterns, be better classified as adenocarcinomas. Keratin immunophenotyping of a cervical carcinoma may become useful in the differential diagnosis of cervical nonkeratinizing carcinoma and poorly differentiated adenocarcinoma.

The most interesting observations in this study were the significant differences between known keratin expression patterns previously observed in frozen tissues and those observed in formalin fixed paraffin embedded tissues. The observation that modifications to staining procedures often enhanced our results considerably, or gave positive results where they had previously been negative, indicate that caution is necessary when interpreting immunohistochemical results, and one should take into account the immunohistochemical procedures used.

In differential diagnostic considerations keratin phenotypes have been shown to be of some value in the differentiation of different types of carcinomas. For example, immunostaining for keratin 10 may distinguish a keratinizing carcinoma, from a nonkeratinizing carcinoma even in the absence of morphologically evident keratinization. As the keratinizing carcinoma is considered to have a poorer prognosis by some [24], investigations into the relationship between keratin expression and the prog-

nosis of squamous cell carcinoma seem necessary. Keratin 7 has been shown to distinguish between adenocarcinoma of the cervix, which is positive, and adenocarcinoma of the colon, which is negative. When the antibody OV-TL 12/30 is used, mesothelioma can be distinguished from certain carcinomas, which may be especially important in cytologic preparations [1]. The observation that the keratin staining patterns of the different types of carcinomas in paraffin sections were less complex and differences more pronounced than observed in frozen tissue sections, can be advantageous to the classification of cervical carcinomas on the basis of these keratin staining patterns. For instance, keratin 8 is not detectable in paraffin embedded, keratinizing carcinomas, while it is usually detected in the nonkeratinizing variety.

These differential staining characteristics therefore make the set of monoclonal keratin antibodies described here applicable in routine diagnostic pathology.

Based on individual keratin expression patterns it is possible to classify the various types of cervical cancer more accurately. This new classification scheme in which the keratin phenotype is important in determining the exact classification of the carcinoma, could then be correlated to the clinical variables of individual patients. In this way it may be possible to relate differentiation, as indicated by keratin expression, to the biological behaviour of the tumour. Recent studies into the presence of vimentin in cervical adenocarcinoma have shown that expression of this intermediate filament protein in the tumour cells is related to a poorer prognosis [19].

Another question with important practical implications is whether or not it is possible to distinguish a group of patients with progressive CIN lesions. As we have pointed out, a subgroup of CIN lesions expresses keratins 8, 18 and 17. We are investigating whether or not this group of patients have a progressive lesion, by comparing keratin patterns to human papillomavirus expression or the presence of certain oncogenes.

**Acknowledgements.** The authors wish to acknowledge the excellent technical assistance of Mr A. Pronk, Mr H. Lijser, Mrs H. Drouen and Mrs M. Konijnenburg. We also thank Dr E. B. Lane, Dr L. Poels and Dr C. van Niekerk for kindly providing antibodies.

## References

1. Baars J, Ruijter JLM de, Smedts F, Niekerk van, Poels LG, Seldenrijk CA, Ramaekers F (1994) The applicability of a keratin 7 monoclonal antibody in routinely PAP-stained cytological specimens for the differential diagnosis of carcinomas. *Am J Clin Pathol* 101:257-261
2. Battifora H, Kopinski M (1986) The influence of protease digestion and duration of fixation on the immunostaining of keratins. A comparison of formalin and ethanol fixation. *J Histochem Cytochem* 34:1095-1100
3. Broers JLC, Ramaekers FCS, Klein Rot M, Oostendorp T, Huysmans A, Muijden GNP van, Wagenaar SSc, Vooijs GP (1988) Cytoskeleton in different types of human lung cancer as monitored by chain-specific monoclonal antibodies. *Cancer Res* 48:3221-3229

4. Cooper D, Schermer A, Sun TT (1985) Classification of human epithelia and their neoplasms using monoclonal antibodies to keratins: strategies, applications and limitations. *Lab Invest* 52:243–256
5. Dallenbach-Hellweg G, Lang G (1991) Immunohistochemical studies on uterine tumours. I. Invasive squamous cell carcinomas of the cervix and their precursors. *Pathol Res Pract* 187:36–43
6. Gigi-Leitner O, Geiger B, Levy R, Czernobilsky B (1986) Cytokeratin expression in squamous metaplasia of the human uterine cervix. *Differentiation* 31:191–205
7. Gown AM, Vogel AM (1984) Monoclonal antibodies to human intermediate filament proteins. Distribution of filament proteins in normal human tissues. *Am J Pathol* 114:309–321
8. Gown AM, Vogel AM (1985) Monoclonal antibodies to human intermediate filament proteins. III. Analysis in tumors. *Am J Clin Pathol* 84:413–424
9. Ivanyi D, Ansink A, Groeneveld E, Hageman PC, Mooi WJ, Heintz APM (1989) New monoclonal antibodies recognizing epidermal differentiation-associated keratins in formalin-fixed paraffin embedded tissue. Keratin 10 expression in carcinoma of the vulva. *J Pathol* 159:7–12
10. Lane EB, Alexander CM (1990) Use of keratin antibodies in tumor diagnosis. *Semin Cancer Biol* 1:165–179
11. Lauerová L, Kovarik J, Bartek J, Rejthar A, Vojtesek B (1988) Novel monoclonal antibodies defining epitopes of human cytokeratin 18 molecule. *Hybridoma* 7:495–504
12. Levi R, Czernobilsky B, Geiger B (1988) Subtyping of epithelial cells of normal and metaplastic human uterine cervix, using polypeptide-specific cytokeratin antibodies. *Differentiation* 39:185–186
13. Makin CA, Bobrow LG, Bodmer WF (1984) A monoclonal antibody to cytokeratin for use in routine histopathology. *J Clin Pathol* 37:975–983
14. Malecha MJ, Miettinen M (1991) Expression of keratin 13 in human epithelial neoplasms. *Virchows Archiv [A]* 418:249–254
15. Moll R, Franke WW, Schiller DL, Geiger B, Krepler B (1982) The catalogue of human cytokeratins: patterns of expression in normal epithelial tumors and cultured cells. *Cell* 31:11–24
16. Moll R, Levy R, Czernobilsky B, Hohlweg-Majert P, Dallenbach-Hellweg G, Franke WW (1983) Cytokeratins of normal epithelia and some neoplasms of the female genital tract. *Lab Invest* 49:599–610
17. Moll R, Schiller DL, Franke WW (1990) Identification of protein IT of the intestinal cytoskeleton as a novel type I cytokeratin with unusual properties and expression patterns. *J Cell Biol* 111:567–580
18. Niekerk CC van, Jap PHK, Ramaekers FCS, Molengraft F van de, Poels LG (1991) Immunohistochemical demonstration of keratin 7 in routinely fixed paraffin embedded human tissues. *J Pathol* 165:145–152
19. Oka D, Nakano T, Tatsuo A (1992) Adenocarcinoma of the cervix treated with radiation alone: prognostic significance of S-100 protein and vimentin immunostaining. *Obstet Gynecol* 79:347–349
20. Purkis PE, Steel JB, Mackenzie IC, Nathrath WBJ, Leigh IM, Lane EM (1990) Intermediate filament markers of basal cells in complex epithelia. *J Cell Sci* 97:39–50
21. Ramaekers FCS, Puts JJG, Moesker O, Kant A, Huysmans A, Haag D, Jap PHK, Herman CJ, Vooijs GP (1983) Antibodies to intermediate filament proteins in the immunohistochemical identification of human tumours, an overview. *Histochem J* 15:691–713
22. Ramaekers FCS, Niekerk C van, Poels L, Schaafsma E, Huijsmans A, Robben H, Schaart G, Vooijs GP (1990) Use of monoclonal antibodies to keratin 7 in the differential diagnosis of adenocarcinomas. *Am J Pathol* 136:625–641
23. Ramaekers F, Smedts F, Vooijs GP (1992) Keratins as differentiation markers in tumour biology and in surgical pathology. In: Spandidos D (ed) *Current perspectives in molecular and cellular oncology*. JAI Press, London, pp 285–318
24. Reagan JW, Fu YS (1979) Histologic types and prognosis of cancers of the uterine cervix. *Int J Radiat Oncol Biol Phys* 5:1015–1020
25. Smedts F, Ramaekers F, Robben H, Pruszczynski M, Muijen G van, Lane B, Leigh I, Vooijs GP (1990) Changing patterns of keratin expression during progression of cervical intraepithelial neoplasia. *Am J Pathol* 136:657–668
26. Smedts F, Ramaekers F, Troyanovsky S, et al. (1992) Basal cell keratins in reserve cells and a comparison with their expression in cervical intraepithelial neoplasia. *Am J Pathol* 140:601–612
27. Smedts F, Ramaekers F, Troyanovsky S, Pruszczynski M, Link M, Lane B, Leigh I, Schijf Ch, Vooijs GP (1992) Keratin expression in cervical cancer. *Am J Pathol* 141:497–511
28. Smedts F, Ramaekers F, Leube RE, Keijser K, Link M, Vooijs P (1993) Expression of keratins 1, 6, 15, 16 and 20 in normal cervical epithelium, squamous metaplasia, cervical intraepithelial neoplasia and in cervical carcinoma. *Am J Pathol* 142:403–412
29. Troyanovsky SM, Geulstein VI, Tchipysheva TA, Krutovskikh VA, Bannikov GA (1989) Patterns of expression of keratin 17 in human epithelia: dependency on cell position. *J Cell Sci* 93:419–426
30. Weikel W, Wagner R, Moll R (1987) Characterization of sub-columnar reserve cells and other epithelia of human uterine cervix. Demonstration of diverse cytokeratin polypeptides in reserve cells. *Virchows Arch [B]* 54:98–110